

Case Report

Prior Roux-en Y Gastric Bypass (Percutaneous)

St. Thomas Hospital
London, United Kingdom

THE FUTURE IN
BIODEGRADABLE
GI PRODUCTS

ARCHIMEDES

Biodegradable Biliary and Pancreatic Stent



79 y/o male patient with prior Roux-en Y gastric bypass surgery due to gastric cancer (15 years prior) presented with a stricture at the Common Bile Duct (CBD) of uncertain etiology.

Patient also had a percutaneously inserted biliary drainage catheter which was a significant inconvenience for the patient.

Percutaneous Transhepatic Cholangiography (PTC) was conducted to retrieve tissues samples via brushing at the level of the stricture and to place an **ARCHIMEDES** biodegradable stent to replace the external drainage catheter and treat the stenosis.

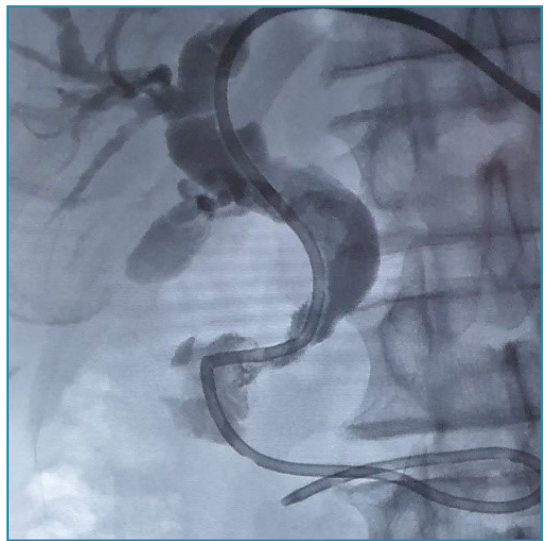


Image 1. Fluoroscopic view showing the drainage catheter and the CBD stenosis.

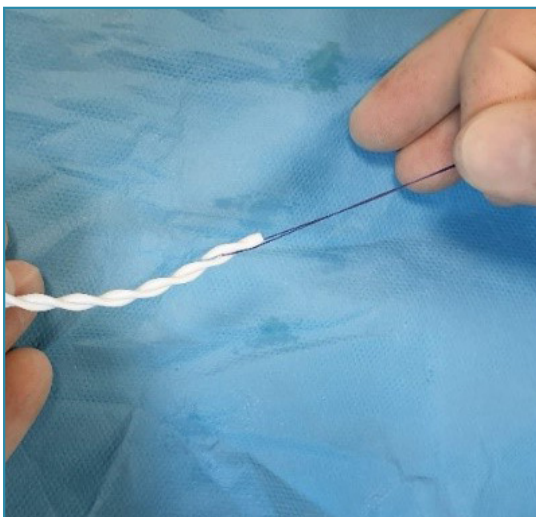


Image 2. Absorbable 2-0 "holding suture" utilized to prevent dislodgment of first stent by second stent.

The patient's existing drainage catheter was removed and direct enteroscopic visualization and brushings at the level of the stricture of the CBD was performed via the SpyGlass™ DS Direct Visualization System.

A 10 F x 30 cm Peel-Away® introducer sheath set was utilized to introduce a 10 mm dilatation balloon.

Given the diameter of the CBD, the decision was made to implant two (2) slow degrading, 8 F **ARCHIMEDES** biodegradable stents, side-by-side.

Case Report

Prior Roux-en Y Gastric Bypass (Percutaneous)

St. Thomas Hospital
London, United Kingdom

The 2-0 absorbable suture was selected to be used as a holding suture around the anti-migration flange of the first **ARCHIMEDES** stent (image 2), in order to retain control and position of the stent, while placing the second stent into place.

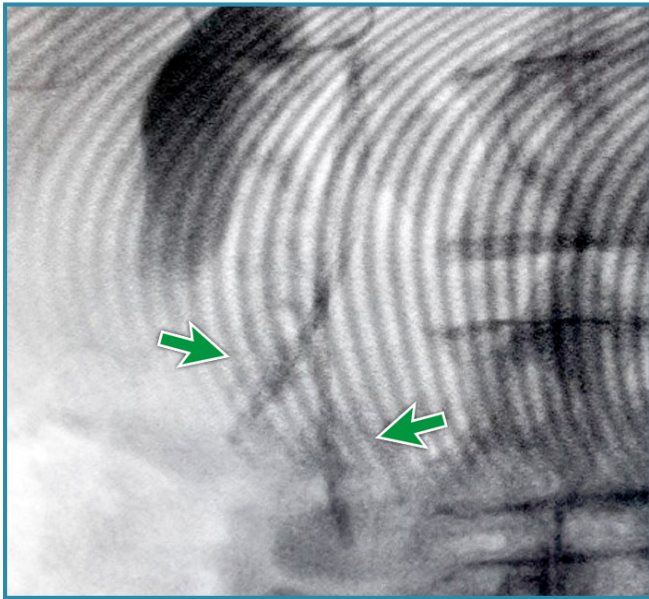


Image 3. Fluoroscopic image showing position of both **ARCHIMEDES** stents.

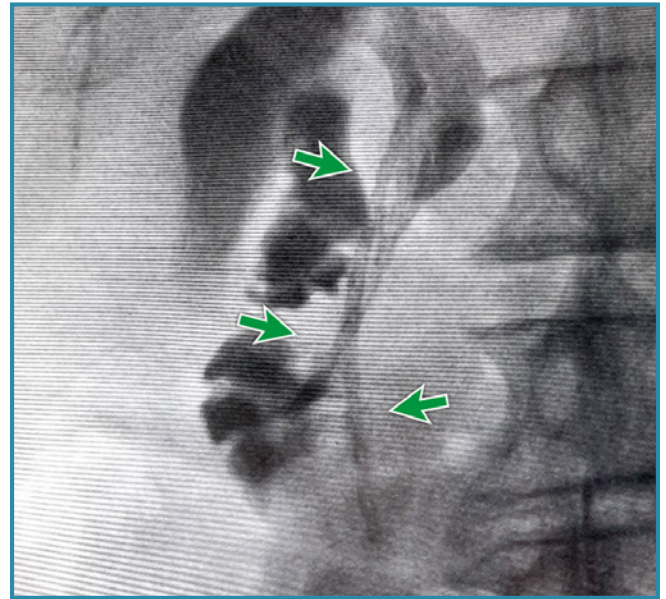


Image 4. Final cholangiogram of **ARCHIMEDES** stents in place.

The **ARCHIMEDES** stent was introduced into the sheath, over the wire, with the holding suture in place and pushed via an 8 F pusher catheter. Following the successful implantation of the first stent, the second stent was implanted utilizing a similar technique, while holding the first stent in position with the holding suture in order to insure accurate placement of both stents. After successful implantation of the second stent, the holding suture was then removed without issue.

amginternational
A Q3 Medical Company

amg International GmbH | Boschstraße 16 | D-21423 Winsen | Germany

Phone +49 4171 6905 57-0
Fax +49 4171 6905 57-11

Email info@amggastro.com
Web www.amggastro.com

Manufactured by
QualiMed Innovative Medizinprodukte GmbH
Boschstraße 16 | D-21423 Winsen | Germany | www.qualimed.de

CCR_ABS_008
Rev.01 02-2020